

## Ocular lavage systems for horses and donkeys

Ocular lavage systems offer a reliable and efficient method for delivery of topical medications for the eye. Their use is indicated where horses or donkeys are fractious (which may be due to the pain caused by the ocular problem), or when topical medication needs to be instilled frequently. It greatly increases compliance by the owner as it is an easy system to use and provides effective treatment as the medication is more likely to contact the eye. There is less wastage of medication from failed application attempts. The safety for the patient and for the owner is greatly improved. Once successfully positioned, an in-dwelling ocular lavage system may be left in place for up to four weeks, which is longer than is required to treat most conditions. They are also very useful for post-operative treatment after ocular surgery.

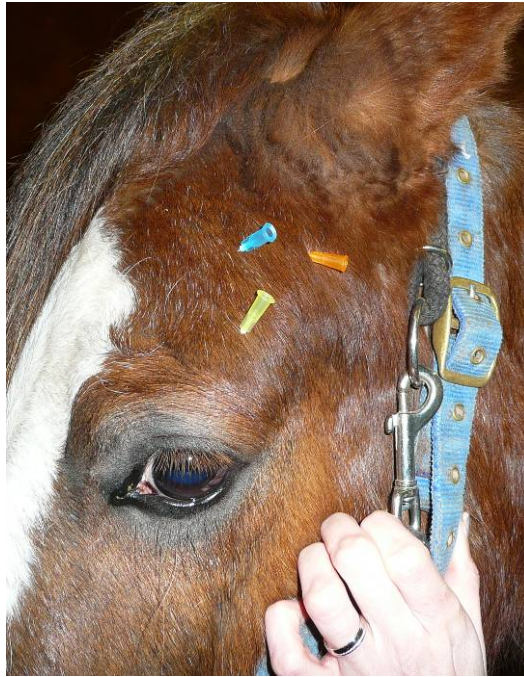There are two types of ocular lavage system – those which are left in-dwelling in the nasolacrimal duct, and those which are inserted under the eyelids (sub-palpebral). The sub-palpebral system may be used in the upper or lower eyelid. The author's preference is the sub-palpebral system placed in the lower eyelid as this site has many advantages. There is great protection afforded to the globe by the third eyelid, making contact of the foot-plate with the cornea less likely. The lower eyelid is also less mobile than the upper eyelid during blinking, thus less movement of the lower eyelid means that the foot-plate is less likely to be dislodged due to blinking. Another advantage is the ease of placement in the lower eyelid. Photographs included in this article are images of the procedure for placing an in-dwelling ocular lavage system in the lower eyelid.

Ocular lavage systems are available commercially, although some people prefer to make their own. A reference is given below which describes the construction of such a system, and this article is free to download from IVIS (<http://www.ivis.org/proceedings/AAEP/1997/White.pdf>). Commercial kits are reasonably expensive, but the cost may be off-set against expected more rapid healing due to patient and owner compliance, and less wastage of topical medications.

An example of commercially available kits is the V-OLK5-90 which is 5 French gauge. The kit is composed of a sharp tunnelling trochar, a silicone catheter with an end base-plate and a Luer lock injection cannula. Additional equipment which is required includes sedation drugs, local anaesthetic (lignocaine or mepicacaine), topical anaesthetic (e.g. 1% proxymetacaine), needle holders, forceps, scissors, tape and suture material (2/0 or 3/0 monofilament nylon or polypropylene).

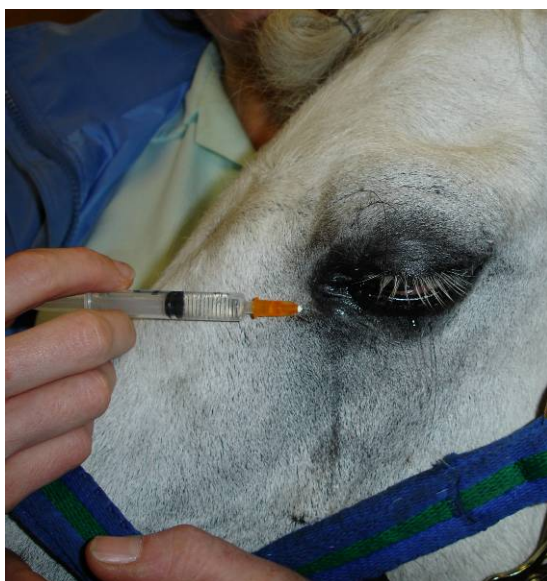### Procedure:

The animal needs to be sedated. Nerve blocks are performed. A motor nerve block is performed by anaesthetising the auriculopalpebral branch of the facial nerve (CNVII) which innervates the powerful orbicularis oculi muscle. The nerve can be palpated under the skin at the highest point of the zygomatic arch, and it is blocked by sub-cutaneous infiltration with 2-3ml of lignocaine or mepivacaine using a 25 gauge needle.

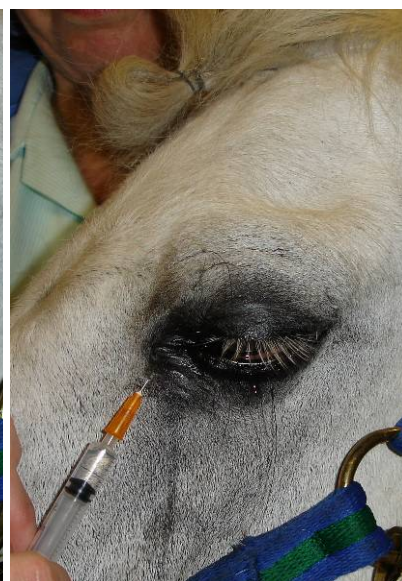


**Figure 1: Three sites where the auriculopalpebral nerve may be blocked.**

A sensory nerve block is performed by anaesthetising the supraorbital nerve, the branch of the Trigeminal nerve (CNV) which is sensory to the central upper eyelid. The nerve exits from the supraorbital foramen within the frontal bone, and it is blocked by the subcutaneous injection of local anaesthetic, as used for the auriculopalpebral nerve block. A combination of these blocks will reduce pain and stop spasm of the orbicularis oculi muscle, allowing the upper eyelid to be lifted and a more thorough examination to be carried out. The eyelids will be flaccid for inserting the ocular lavage system. A local nerve block is achieved by instilling 2-3ml local anaesthetic near the medial canthus, directed medially towards the zygomatic sensory nerve and dorsally towards the lacrimal sensory nerve (Figures 2 and 3). Topical anaesthesia is instilled into the conjunctival sac.

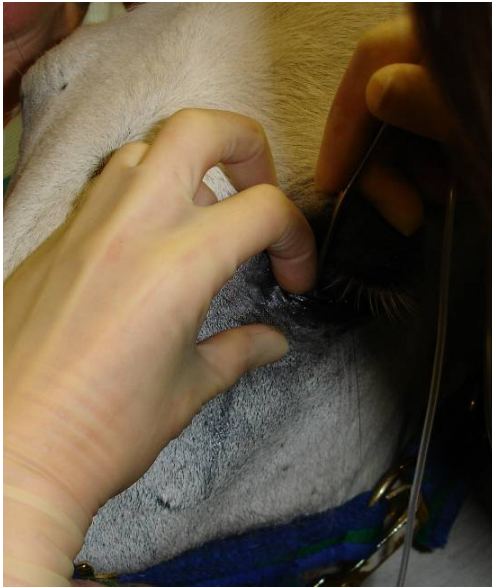

**Figure 2.**

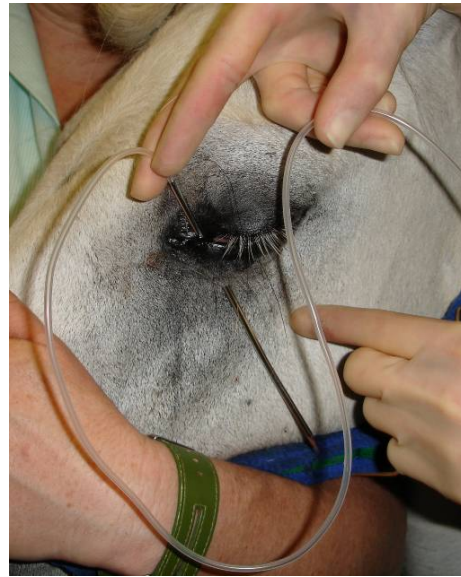

**Figure 3.**

Wearing a surgical glove, the index finger is inserted deep into the conjunctival fornix at the medial aspect of the lower eyelid and directed outwards, to provide a guide for the trochar while protecting the cornea. The tip of the trochar is then inserted deep into the conjunctival sac along the finger, and tunneled through at the base close to the orbital rim to exit on the skin 1-2cm below the eyelid (Figure 4). The tubing is attached to the blunt end of the trochar and then threaded through the exit point (Figure 5), leaving the footplate at the end of the tubing seated deep in the conjunctival sac. The position of the footplate should be carefully checked, ensuring that it is snug in the conjunctival fornix.

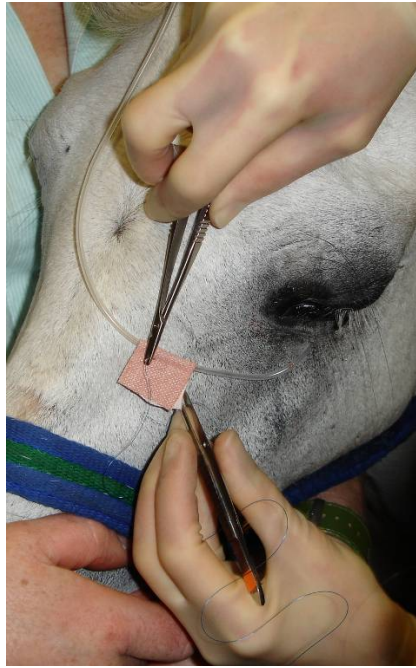

**Figure 4.**

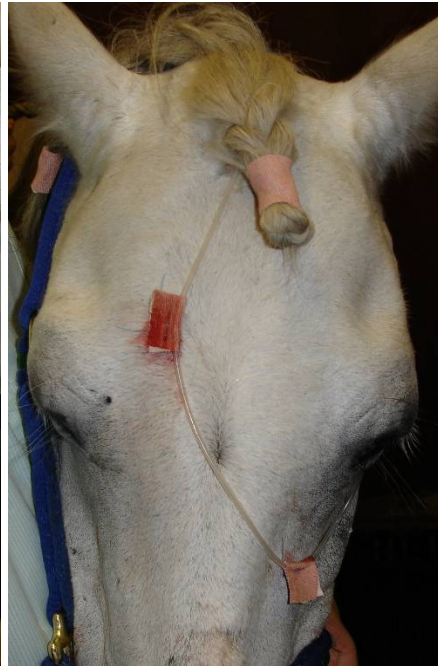

**Figure 5.**

The trochar is removed. The blunt needle from the kit is inserted inside the silicone tubing at the distal end, to which the injection port is attached to seal it. The tubing is then dried carefully in order that tape will adhere to it well. Super-glue may be used to ensure that it stays attached. Tape is applied in a butterfly fashion close to the exit point onto the face (the tape in Figure 6 should be closer to the eye, although the lavage system lasted several weeks the way it was), and the tubing is directed to the centre of the face and brought up through the forelock (a plait at this point is convenient, see Figure 7) to end at a plait on the mane (Figure 8). Kinking must be avoided. Ideally the tubing should end on the opposite side to the affected eye, so that the horse can see the person medicating them, therefore creating less stress. An additional butterfly tape is placed to align with the centre of the forehead. It is advisable at this point to check the patency of the tube before it is sutured into place. The tape is sutured to the skin at the anchoring points, through the full thickness of the skin, and taking care not to tie the sutures too tightly (Figure 6).



**Figure 6.**



**Figure 7.**



**Figure 8.**

0.2ml of the topical medication to be instilled is drawn up in a syringe and injected into the tubing from the injection port. This is followed by a slow injection of sufficient air to allow the medication to reach the eye, approximately 2ml. When multiple medications are required, it is best to wait five minutes in between application of different eye drops. The injection port may wear out after a few days and start to leak, in which case it should be replaced. The lavage system should be checked reasonably regularly. Early replacement of loosening sutures or tapes will ensure that it lasts longer. It should be removed if it is causing problems, or no longer required.

### Complications:

There are potential complications arising from the use of an ocular lavage system. In one study by Giuliano et al (the reference is supplied below):

59% had no reported complications

38% had non-ocular complications including

- 18% were displaced from the conjunctival fornix
- 14% needed re-suturing of the tapes to the skin
- 6% had problems of leakage from the injection port

3% had ocular complications with was minor swelling of the lower eyelid.

However careful placement and good hygiene minimise the incidence of complications.

### References:

Giuliano EA, Maggs DJ, Moore CP, Boland CP, Champagne ES, and Galle LE. (2000). Inferomedial placement of a single-entry subpalpebral lavage tube for treatment of equine eye diseases. *Veterinary Ophthalmology* **3**, 153-156.

White SL (1997) Construction and placement of a subpalpebral lavage system for medication of the eye. *Proceedings of the annual convention of the AAEP* **43**, 160-162.