

Feline Ophthalmology Part I: Examination of the eye

Natasha Mitchell

Downland Veterinary Group, 71 Havant Rd., Emsworth,
Hampshire, PO9 5NH, England

Tel: +44 1243 377141; Email: tashavet@hotmail.com

Introduction

The feline eye is unique in many ways including anatomy, vision, and response to disease. There are also a number of ocular conditions that occur only in cats. Many conditions can be diagnosed from clinical appearance alone. Therefore, familiarity with the normal and the abnormal can assist rapid diagnosis and early instigation of the correct treatment. It is always important to examine the affected eye, but not to neglect the eye that seems normal to the owner. A full history and clinical examination is warranted to glean useful diagnostic information for systemic disease with ocular manifestation. This article is intended to focus on the common feline ocular conditions that regularly present at first opinion veterinary practices, and is presented in two parts. Part 1 considers the unique features of the feline eye, and outlines a step-by-step method to perform a thorough ocular examination. Part 2 describes the clinical presentation of common feline ocular conditions that can be easily diagnosed with basic equipment and a knowledge of the normal eye.

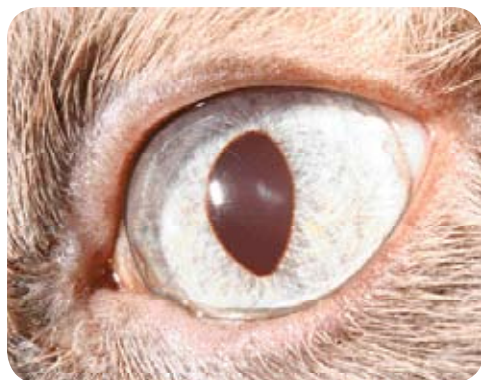

Figure 1: Normal cat's eye; note the visible peripheral iris blood vessels.

Anatomy

Compared to the standard dog's eye, the feline cornea and pupil are larger, allowing more light to enter the eye. Cats have skeletal muscle in their third eyelids, innervated by the abducens nerve (Cranial Nerve VI), which allows them to actively, as well as passively, protrude this structure. The anterior chamber is deeper, allowing the entrance to the ciliary cleft (the drainage angle) to be seen directly with focal illumination (a technique called gonioscopy). The iris is paler in colour and, therefore, the iris vasculature, whether normal or abnormal, is easy to see (Figure 1). The shape of the pupil in domestic cats is a vertical slit when constricted and is round when dilated. The iris sphincter muscle fibres interlace, creating a scissors-like action which allows for almost complete constriction (miosis). The menace response is subtler and difficulties arise with some vision tests, such as the obstacle course. Subtle or unilateral loss of vision can easily go unnoticed.

Vision

Cats have very efficient nocturnal vision. They achieve this with many adaptations including:

- a large cornea, which allows more light into the eye;
- a slit pupil that can dilate 6mm more than a human pupil, allowing more light to enter in dark (scotopic) conditions. It also allows for profound miosis, which protects the rod-dominated retina from damage by bright light;
- a tapetum lucidum, which is a cellular reflecting structure situated behind the retina that reflects 130 times more light than a human fundus.

Feline visual acuity has been estimated to be between 20/100 and 20/200 (Snellen fraction). The retina contains predominantly rod photoreceptors, which function well in scotopic conditions. Both feline and human cones are trichromatic, with functioning red, green and blue photoreceptors. However, behavioral studies suggest that feline colour vision is poor; their ability to distinguish between two coloured stimuli is limited unless they differ greatly in spectral content. Although cats have superior night-vision, they can only accommodate about four dioptres, compared to 14 dioptres in a human infant, or seven to eight dioptres in a 30-year-old adult. Instead of changing the shape of the lens, the cat is able to accommodate by actually moving the lens position.

Preparation for examination of the eye

The ocular examination should be carried out in a routine manner. It is important to complete the standard examination in every case and to avoid the tendency to delve straight into the obvious problem. This will ensure that no other important features of the disease are missed, and allow for a more accurate diagnosis. Both eyes should be examined.

Equipment

Firstly, it is important to consider the equipment available. The animal should be examined in a room that is capable of being darkened. It is helpful if there is an assistant to restrain the animal, keeping the head still, without putting pressure on the animal's neck. A focal light source is required. This can be provided by a simple pen-torch. Other sources may be a Finhoff transilluminator, a direct ophthalmoscope, or an otoscope (Figure 2). Some form of magnification is required. Examples include a direct ophthalmoscope, head-mounted loupes, an indirect ophthalmoscope or a slit-lamp bio-microscope. A hand-held



Figure 2: Direct ophthalmoscope and Finhoff transilluminator.

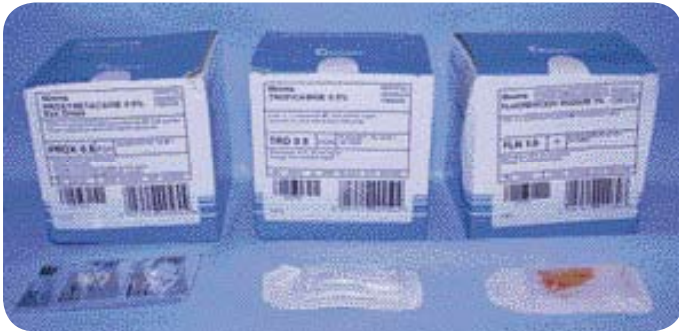

Figure 3: Commonly used topical drops for diagnostics.

condensing lens is very useful and will be discussed later.

Disposable equipment that should be available include fluorescein dye (either as impregnated strips or 1% drops), Schirmer tear tests (Schering-Plough), topical anaesthesia (e.g., proxymetacaine or amethocaine drops), mydriatics (e.g., tropicamide drops), bacteriology swabs, microscope slides, Diff-Quik stain and naso-lacrimal cannulae (**Figure 3**).

Signalment

The breed and age of the animal are considered, along with vaccination history, general health status, current medications and the health of in-contact cats.

History

Accurate history taking is extremely important in every case and all information needs to be recorded. The owner should be asked whether there were any previous eye problems, the duration of the current problem and the progression of the condition.

Examination in a lighted room

Observation from a distance

The animal should be observed with minimal restraint as it becomes more familiar with the new environment of the consulting room. Signs of poor vision should be noted, such as a reluctance to jump, or bumping into things. Conformation of the head is considered; brachycephalic cats such as Persians have relatively prominent eyes. Facial symmetry and position of the eyes should be assessed, e.g., protruding globe (exophthalmos), deviation of gaze (strabismus), differences in palpebral fissures (**Figure 4**). Ocular discharges and their nature are noted, e.g., epiphora /mucoïd /purulent etc. Signs of ocular pain are evidenced by blepharospasm, epiphora, photophobia and head shyness.



Figure 4: Left sided facial nerve paralysis causing narrowing of the palpebral fissure on the affected side.

Observation close-up

Colour changes are noted, e.g., white, blue, or red. Eyelid anatomy and their mobility are examined. Testing the menace response involves moving the hand towards the eye in a threatening manner, taking care not to create an air current. This is a learned response, and will be absent in kittens of less than 12 weeks of age. It is a crude assessment of vision, and involves the optic nerve (Cranial Nerve II), the facial nerve (Cranial Nerve VII), and a complicated pathway through the cerebellum. Therefore a cat with cerebellar disease may have normal vision with an absent menace response. The medial and lateral palpebral reflexes are assessed by touching the lateral and medial aspects of the eyelid aperture. These test the integrity of the trigeminal nerve (Cranial Nerve V) and the facial nerve. The oculovestibular reflex, also called the “doll’s head reflex”, is tested by slowly moving the head from left to right and from an upward to a downward position. A normal physiological nystagmus is expected to be present if the oculomotor (Cranial Nerve III), the abducens (Cranial Nerve VI) and vestibular (Cranial Nerve VIII) nerves are intact. The pupillary light response (PLR) is assessed when a focal light is shone into the lateral aspect of the eye. A functioning optic nerve and oculomotor nerve will result in constriction of the pupil of the stimulated eye, along with a consensual or indirect response in the other eye.

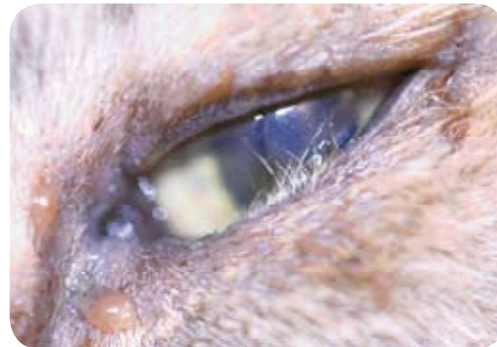

Figure 5: Entropion causing trichiasis.

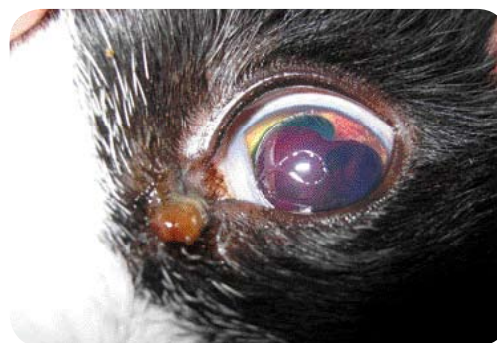

Figure 6: Blood clot in anterior chamber (hyphaema), with iris synechiae from one to three o'clock, caused by hypertension.

Vision may be assessed with a combination of the menace response, dazzle reflex, tracking response to cotton balls, placing reflexes, and behaviour in an unfamiliar environment. Note a non-visual eye may have a normal PLR: for example, in the presence of a cataract. Similarly, a visual eye may have an absent PLR: for example, with paralysis of the oculomotor nerve.

The lid margins are examined for any masses or hairs rubbing on the globe (distichia, trichiasis or ectopic cilia; **Figure 5**). The bulbar and palpebral conjunctiva are examined. The third eyelid is protruded by placing gentle digital pressure on the globe. The clarity,

or any interruptions to the clarity, of the cornea is noted. The anterior chamber may be examined for depth (it is much deeper in the case of posterior lens luxation) and for contents, e.g., blood (**Figure 6**), fibrin (**Figure 7**), inflammatory cells, lipid or the lens. The iris size, shape, colour and symmetry are observed.

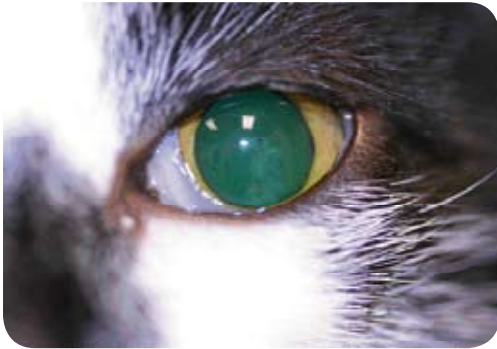

Figure 7: Fibrin in the anterior chamber as a sequel to uveitis.

Examination in a darkened room

The dazzle reflex is assessed by shining a bright light into the eye. A partial blink response indicates an intact reflex. As this is a sub-cortical reflex, a cat with cortical blindness may have a positive dazzle reflex. Distant direct ophthalmoscopy is a useful technique (**Figure 8**). With

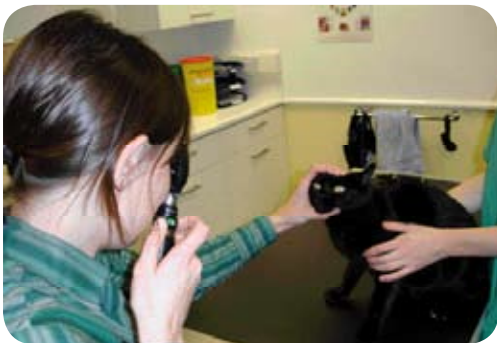

Figure 8: Distant direct ophthalmoscopy.

the animal at arm's length, the tapetal reflection is found by looking through the ophthalmoscope (with the lens magazine set to zero) and observing the reflex from both eyes. Opacities in the visual axis are easily seen. Anisocoria (pupils of different sizes, **Figure 9**), cataracts, nuclear sclerosis, retinal detachment, and aphakic crescent of lens luxation are some of the conditions picked up using this technique. Parallax may be used to ascertain whether a lesion is anterior to, posterior to, or within the lens. This technique is very useful in

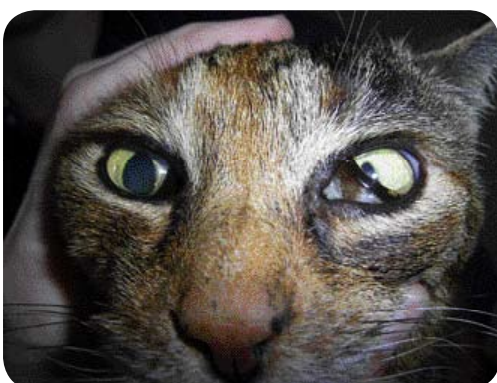


Figure 9: Horner's syndrome in the left eye with ptosis (drooping of the upper lid), prolapse of the third eyelid, miosis and enophthalmos.

assessment of the presence of cataracts; a dense cataract will block the observer's view of the tapetal reflection.

The PLR is repeated, as some abnormalities are best picked up under different lighting conditions (e.g., Horner's syndrome). Focal light examination is repeated in the darkened room, using magnification provided by a direct ophthalmoscope (with lens set to +10 to +20), an otoscope or a slit-lamp biomicroscope.

A form of magnification (e.g., direct ophthalmoscope) is used to examine the lids, lacrimal punctae, conjunctiva, third eyelid, cornea, anterior chamber, iris and lens. The use of the slit beam allows the thin beam of light to make an optical section through the eye, facilitating the exact localisation of the lesion, e.g., the depth of a corneal ulcer. A slit-lamp biomicroscope is a valuable instrument used for this purpose at referral centres, although its expense prohibits its use in general practice.

Examination of the fundus (fundoscopy) is easier to perform after dilation of the pupils. This can be achieved by application of topical tropicamide (0.5% or 1%) and waiting 15 to 20 minutes. The fundus may be assessed by the direct method with the direct ophthalmoscope (most commonly done in practice), or by the indirect method (the author's preferred method, **Figure 10**).

Using the direct ophthalmoscope, set the lens wheel to zero and place it very close to the cat's eye. The clinician's right eye should be used to examine the cat's right eye and their left to examine the cat's left eye. A small area of the fundus may be examined under almost 20 times magnification. It is similar to looking through a keyhole. It can be quite difficult to examine the entire fundus, as the optic disk needs to be examined along with blood vessels, the entire tapetal fundus and the larger non-tapetal fundus. In addition, the examiner is also very close to the cat's teeth! Indirect ophthalmoscopy is an easy method of examining a large area of the fundus, and the author's preferred method. The technique requires some practice. At arm's length distance from the animal, the tapetal reflection is found with a focal light source. A hand-held condensing lens is placed approximately 2cm in front of the eye, and moved slightly until the image is obtained. This image will be upside-down and back-to-front. Magnification depends on the strength of the lens used (a 20 dioptre lens provides almost twice as much magnification). A wide field of view is obtained, which is much easier to interpret. Condensing lenses are inexpensive, and may be obtained from Veterinary Speciality Products for as little as £25 (€35). A head-mounted indirect ophthalmoscope is used at specialist centres, and allows for binocular examination, giving stereopsis.

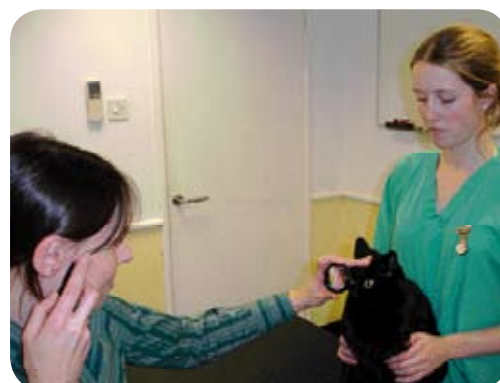

Figure 10: Indirect ophthalmoscopy.

Ancillary tests

Schirmer tear test

This test measures the aqueous component of the tear film and should be carried out in the presence of any ocular surface disease (Figure 11). Keratoconjunctivitis sicca is an overlooked condition in cats. Normal tear production is 10 to 15mm in one minute, but the results need to be interpreted in light of clinical findings. This test should be performed first, before any other drops are applied to the eye.

Bacteriology, virology, cytology

A bacteriology swab should also be taken before drops are applied to the eye, as they often contain bacteriostatic components. There is a varied resident bacterial flora, on the surface of the eye (discussed in part two), which means results need to be interpreted with caution. In the case of a serious ocular infection (e.g., in the case of a melting ulcer), it is very important to perform cytology. A cytology scraping should be taken with care from the edge of the affected area, and a Gram stain used to determine whether a Gram-positive or a Gram-negative infection is present. This allows the correct antibiotic to be chosen, before the condition progresses to rupture of the globe.

Swabs taken from the conjunctiva and from the nasopharynx may be submitted as plain swabs and in viral culture transport medium for the PCR diagnosis of feline herpes virus 1 (FHV-1) and *Chlamydomphila* sp. (formerly *Chlamydia psittaci* var *felis*), or virus isolation of FHV-1 and feline calicivirus.

Fluorescein staining

Fluorescein is a hydrophilic and lipophobic stain. If the corneal epithelium is intact, there is no uptake of the stain. A breach in the epithelium is easily seen with a cobalt blue light as a brilliant green staining of the stroma. Descemet's membrane does not take up this stain. Thus care must be taken not to interpret a deep corneal ulcer, which exposes Descemet's membrane (a descemetocoele) and does not take up the stain, as an intact epithelium. Ulceration due to FHV-1 may take the form of dendritic ulcers, which are very fine and branching (Figure 12), and may be more easily seen with rose bengal stain.

Fluorescein travels down the tear duct and may be visible at the nares within five to 15 minutes. This is called a positive Jones test, and shows nasolacrimal duct patency. A negative Jones test needs to be interpreted with caution as the ducts may empty into the

nasopharynx (especially in brachycephalic cats).

If the eye is ruptured, the fluorescein mixes with the aqueous fluid, which is easily seen and called a positive Siedel's test.

Tonometry

Assessing intraocular pressure allows the clinician to know whether ocular hypertension, which contributes to glaucoma, is present. Digital assessment is crude and unreliable. A Schiøtz tonometer is a relatively inexpensive piece of equipment and, with correct cleaning care, can produce very accurate readings. However, many cats resist this procedure. The applanation tonometer (e.g., Tono-Pen®) measures intraocular pressure by measuring the force required to flatten a tiny area of cornea. It is simple to perform, and can be done in the presence of significant corneal disease. This instrument, however, is much more expensive than the Schiøtz tonometer.

Gonioscopy

At the opening into the drainage angle is the ciliary cleft and pectinate ligaments, and these can be directly examined in the cat without the need for a goniolens. Only magnification and a light source are required, but it is important to be familiar with the normal.

Imaging techniques

Radiography, ultrasound imaging and magnetic resonance imaging (MRI) may be indicated with certain ocular conditions. Radiography can be used to assess orbital fractures or to identify gun-shot pellets. Ultrasound can be done on the conscious animal using a 12.5 megahertz probe directly applied to the cornea, and is useful to assess cataracts or lens luxation and view retinal detachments, ocular foreign bodies, intraocular masses or retrobulbar masses. Cats may be referred for MRI testing.

In summary, it is essential to perform a full clinical examination of the patient to assess whether systemic disease is contributing to the problem and then to carry out a thorough examination of both eyes. The clinician should ascertain if the eye is visual or painful, whether abnormalities present are normal variants or pathological, and if a condition is progressive. The aims are to diagnose the condition and to advise the client on treatment methods available and on the expected outcome.

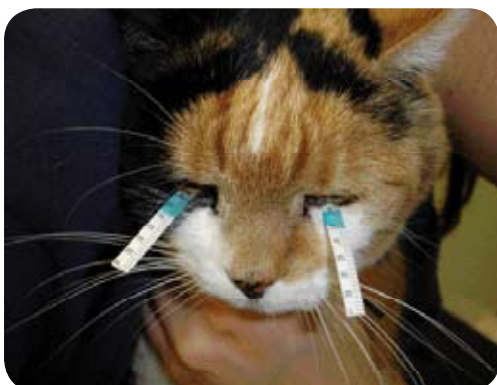


Figure 11: Schirmer tear test in both eyes.

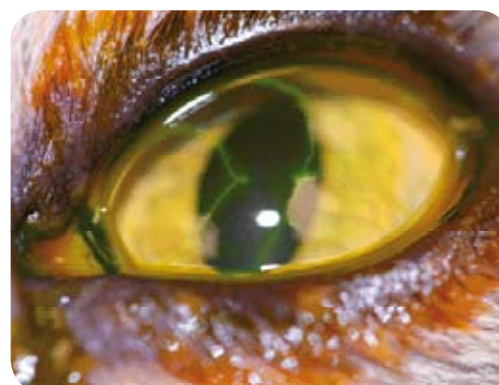

Figure 12: Fluorescein uptake in the case of dendritic corneal ulceration caused by FHV-1 infection.