

Corneal sequestrum in cats – self assessment

Natasha Mitchell, Eye Vet, Crescent Veterinary Clinic, Dooradoyle Rd,
Limerick
www.eyevet.ie

1. Describe the abnormalities in Figure 1.
2. What's your diagnosis? How does the condition typically present?
3. What causes this condition?
4. How is this condition managed?
5. What is the prognosis?

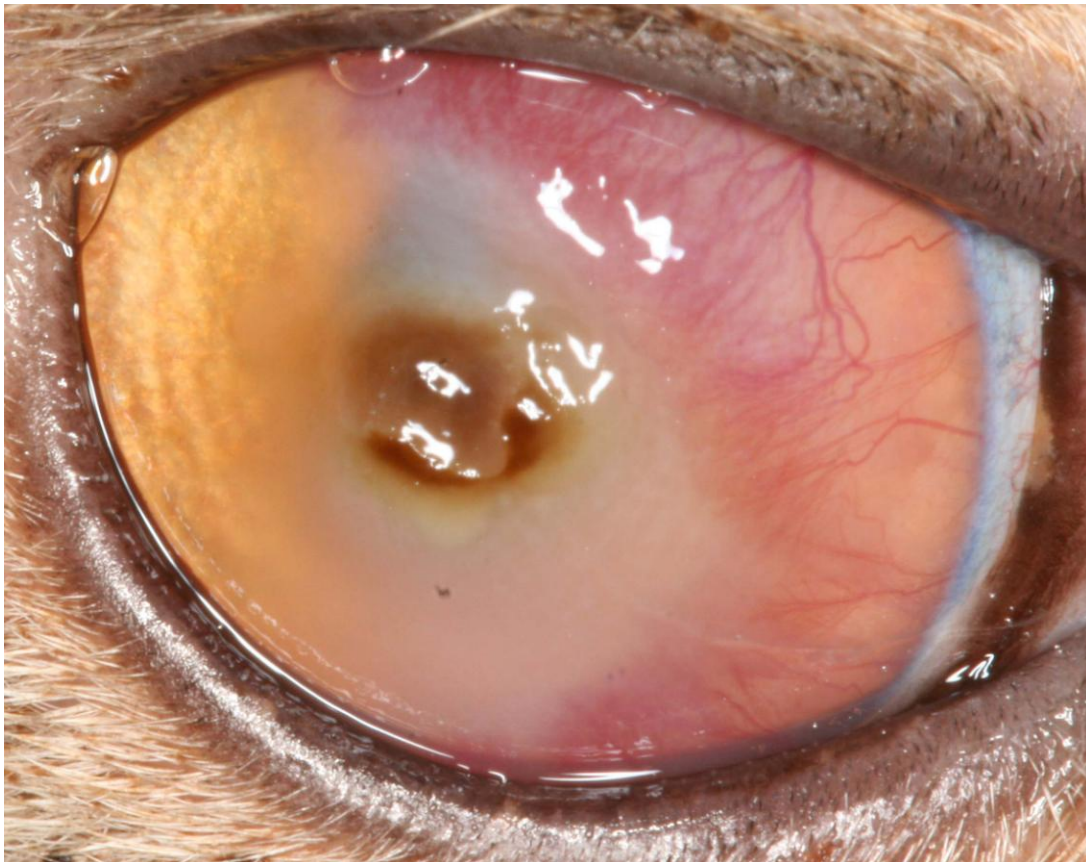


Figure 1.

1. Describe the abnormalities in Figure 1.

There is a 4mm diameter brown raised irregular circular area axially surrounded by corneal oedema and infiltrate. There are multiple arborising superficial corneal vessels extending from the limbus towards the lesion from the superior, nasal and inferior aspects, along with deep stromal vessels.

2. What's your diagnosis? How does the condition typically present?

The appearance is pathognomonic for feline corneal sequestrum. This condition is typified by oval to round, tan to black focal discoloration of the central or paracentral cornea. The intensity of corneal staining of the affected stroma varies, ranging from a light tea-stain (figure 2) to a dark black opaque plaque (figure 3), and the lesion may become progressively darker with time. There is a varying degree of surrounding inflammation and vascularisation (figure 4), usually depending on the how long the necrotic stroma is present. The sequestrum may be raised above the corneal surface, from where it may eventually naturally slough (figure 5). The depth of the necrotic tissue within the stroma varies – it most commonly affects the anterior third of the stroma but may progress to extend to Descemet's membrane, where it could potentially lead to corneal perforation.

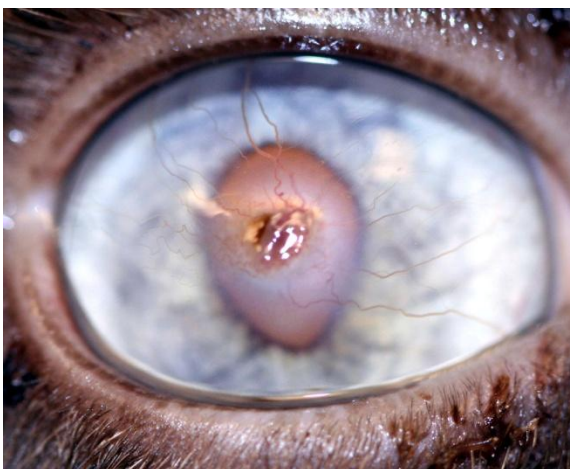

Fig 2 – The right eye of a Siamese cat which had a chronic corneal ulcer which developed a small deep sequestrum underneath non-adhered epithelium

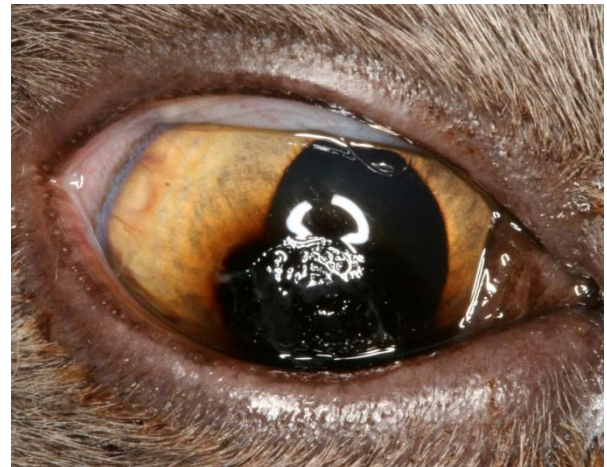

Fig 3 – A very large sequestrum in a ten-year-old Burmese cat with minimal neovascularisation

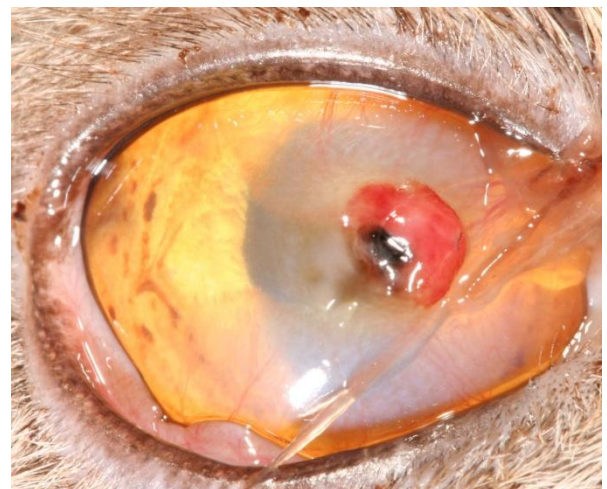

Fig 4 – The left eye of a Burmese cat with muroid ocular discharge and a chronic corneal sequestrum which evoked a foreign-body type reaction with fibrovascular infiltration of the area as the cornea starts to reject the sequestrum

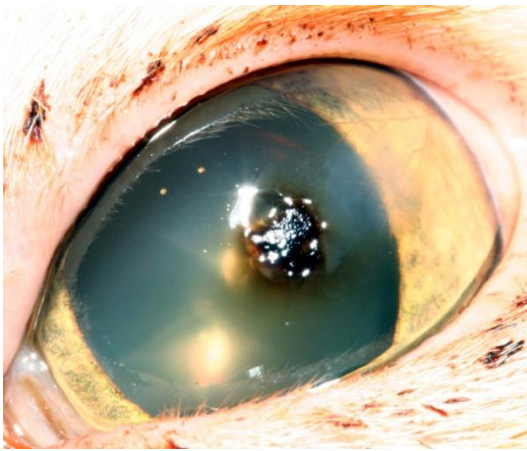


Fig 5 – The left eye of a Domestic Short-haired cat with a central focal corneal sequestrum which was protruding from the surface of the cornea

Many cats have chronic ocular disease for weeks, months or years, and once the lesion develops it can remain static or cause persistent problems for months to years. The degree of discomfort experienced by the cat varies, and is expressed by blepharospasm and ocular discharge, which may be darkly staining. Some initially present with superficial corneal ulceration, within which an amber staining starts to become apparent. Once developed, uptake of fluorescein on top of the sequestrum cannot be appreciated, but there may be uptake at the edges of the lesion and in adjacent cornea (figure 6).

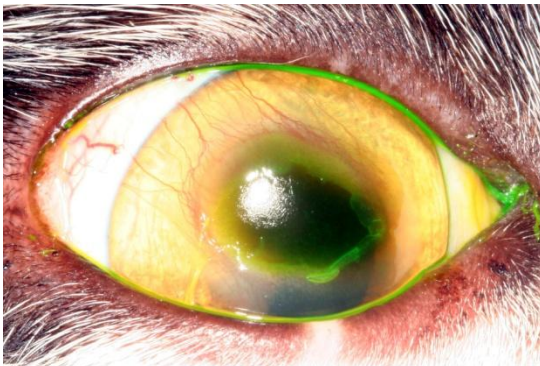


Fig 6 – The right eye of a Domestic Short-haired cat which had a chronic corneal epithelial defect with non-adhering epithelium visible at the edges of the sequestrum which later developed

This condition is almost unique to cats (it occurs rarely in horses). Cats of any breed may be affected, although there is a breed pre-disposition for Persians, Himalayans, Siamese, Burmese and Exotic Shorthaired cats. Usually one eye is affected, except in the pre-disposed breeds when two eyes may be affected simultaneously or at different times.

The cat featured in figure 1 is a one-year-old Exotic short-haired cat which had the left eye previously enucleated as a result of a corneal sequestrum which resulted in corneal rupture (figure 7), therefore saving the right eye was very important to the owner.



Fig 7 – The cat featured in Figure 1 which had her left eye enucleated due to a corneal sequestrum which progressed to cause globe rupture when she was a kitten.

3. What causes this condition?

The sequestrum represents an area of stromal collagen degeneration with accumulation of pigment. The discolouration is likely to consist of multiple components, those proposed include melanin, haemosiderin, and iron. Dessication of the necrotic stroma, mineralization and apoptosis of keratocytes may also play a role.

A variety of factors contribute to the initiation of sequestrum formation. These include brachycephalic conformation, lagophthalmos, mechanical irritation such as trichiasis from entropion, chronic corneal ulceration, feline herpesvirus (FHV-1) infection, tear film abnormalities, corneal trauma, topical corticosteroid administration, and primary corneal dystrophy. Facial configuration of brachycephalic breeds predisposes them to central corneal exposure. A combination of these predisposing factors causes corneal damage. It is widely accepted that corneal insult initiates the disease, with the presence of other complicating factors adversely affecting healing, allowing chronic and substantial epithelial and stromal damage. Iatrogenic damage from previous therapeutic interventions in an attempt to stimulate healing of chronic corneal ulcers may cause a corneal sequestrum. It has been shown that cats subjected to a grid keratotomy for a chronic indolent ulcer are more likely to develop a corneal sequestrum, and for this reason the procedure is best avoided. A recent study found *Toxoplasma gondii* on PCR in four out of nine cases.

FHV-1 is frequently incriminated as a principle cause of corneal sequestration but a definitive relationship has not been proven. FHV-1 testing should be considered, although the tests do not have 100% sensitivity. The significance of FHV-1 in corneal sequestrum is suspected but the results of studies vary. One study found FHV-1 in 55.1% of corneal sequestra specimens and in only 5.9% of healthy specimens. However eight of 66 (12%) samples of corneas from normal cats have been found positive for FHV-1 using PCR, and it has been estimated that over 90% of cats are seropositive for the virus. FHV-1 is not found in all cases of corneal sequestrum and therefore is not the sole agent responsible.

4. How is this condition managed?

The aims of treatment are to provide relief from pain, eliminate the sequestrum, shorten the duration of disease, restore and preserve a clear visual axis, prevent progression to corneal rupture and reduce the likelihood of recurrence. Left untreated, or ideally supported with medical treatment outlined below, the lesion may naturally loosen and then slough off as it is extruded from the cornea leaving another corneal ulcer which should then re-model and heal. The time taken for this to occur varies greatly, and while it can occur in a matter of weeks, it usually takes months or even years before clinical resolution of the condition occurs.

The benefits of conservative medical treatment include avoidance of a general anaesthetic and the associated risks and costs, and it is minimally invasive. Medical treatment involves the use of topical artificial tears two to four times daily and topical antibiotic drops or ointment two to four times daily. Topical steroids should be avoided as they potentiate corneal collagenases which could result in a melting ulcer, and they may also cause recrudescence of FHV-1.

As FHV-1 is frequently implicated in the pathogenesis of the condition, it makes sense to treat with anti-virals. A recent study found that corneal sequestra detached in two out of three cats treated with famcyclovir (Famvir, Novartis). The two which resolved had a dose rate of 62.5mg/cat once daily for seven days and increasing to 62.5mg/cat twice daily for 35 and 43 days respectively. One additional cat had a dose of 62.5mg/cat for an unspecified length of time and did not resolve. It is very interesting to find other potential treatments for this condition, although the limitations of the study included the absence of confirmation of FHV-1 infection, small study number, adjunctive treatment and it was not a masked trial. Famcyclovir dose rates quoted for FHV-1 infection in cats vary hugely from 62.5mg/cat once daily to 90mg/kg three times daily.

The decision as to whether to opt for medical or surgical treatment may be based on the present comfort of the patient, on the apparent risk of deepening disease with potential rupture and on finances available. In many cases medical treatment does not produce satisfactory results and there may be welfare concerns for the cat.

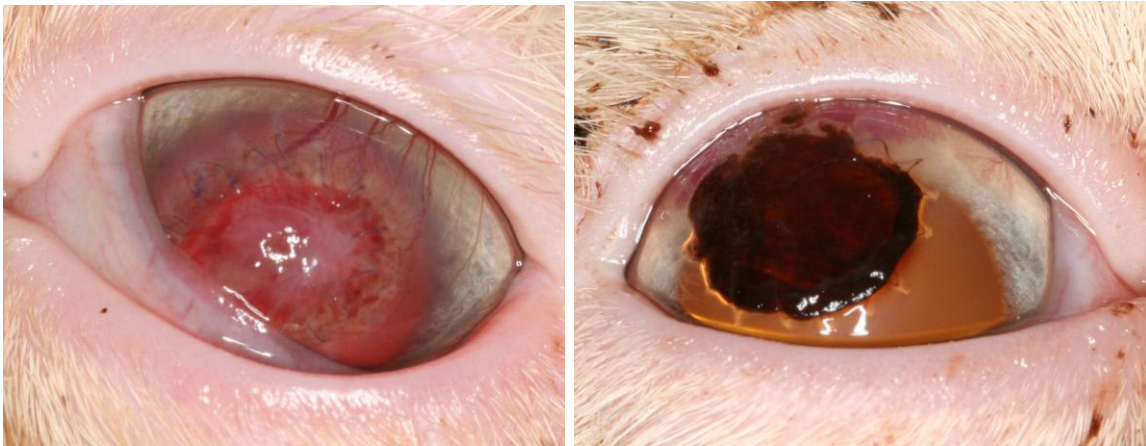
Surgery is often recommended as the treatment of choice to rapidly increase the comfort of the patient. It shortens the duration of discomfort experienced, and reduces the likelihood of recurrence. It also prevents the sequestrum from progressively deepening to the extent where globe rupture may occur. In other words it control pain and provides for rapid healing. The excised tissue may be submitted for histopathology, or more usefully, for nested PCR and virus isolation for FHV-1.

Corneal surgery involves specialised equipment and techniques, and requires some experience. It is important to remove the entire sequestrum, as there may be recurrence if pigment remains at the base or periphery of the keratectomy site.

All surgical techniques start with a keratectomy, which is a lamellar excision of the sequestrum to the depth necessary to obtain a clear cornea. If the sequestrum is superficial, this procedure alone may be sufficient. A soft therapeutic bandage contact lens may be applied in these cases to improve ocular comfort after the procedure. The depth of the lesion is difficult to assess pre-surgery, and therefore the surgeon must always be prepared to perform a grafting procedure. A graft is recommended if excision of the half the corneal width or deeper is required to fully remove the lesion. This may be provided by a conjunctival pedicle, porcine small intestinal sub-mucosa graft, a corneo-conjunctival transposition or a corneal graft. Grafts can potentially cause

scarring of varying density, and this corneal opacity can lead to visual impairment and is unsightly for the owner.

The conjunctival pedicle graft is practical and versatile, rapidly increasing patient comfort, providing physical support with tissue to fill the ulcer and a direct blood supply to the area delivering healing factors and systemically administered antibiotics from the blood supply. The procedure has been suggested to decrease the likelihood of recurrence compared with keratectomy alone. Porcine small intestinal submucosa graft is collagen based and acts as a scaffold on which the cornea can remodel and repair by regeneration. It is translucent and porous. It is best used in vascularised corneas (figure 8). Occasionally the graft rapidly becomes pigmented after surgery (figure 9). Figures 8 and 9 are the left and right eye of the same Persian cat, the Bio-SIS-t graft in the left eye vascularised very quickly whereas pigment invaded the same graft in the right eye within days. Corneo-conjunctival transposition may provide excellent results cosmetically, providing a clear visual axis with no recurrences quoted. It involves transposition with a pedicle of adjacent healthy cornea and its attached bulbar conjunctiva into the site of keratectomy. It provides physical support and blood flow to the diseased area, along with tissue to allow for more satisfactory healing (figure 10). It is technically more difficult to perform than a conjunctival pedicle or small intestinal submucosa graft. Partial thickness (lamellar) or full thickness (penetrating) corneal grafts may be used after keratectomy. Feline or canine donor corneas may be used, and there is potential for excellent optically clear results.



Figs 8 and 9 – The left and right eye of a two-year-old Persian cat which developed corneal sequestra in both eyes. The photos were taken one week after bilateral superficial keratectomy with Bio-SIS-t graft placement. The graft in the left eye vascularised whereas the graft in the right eye became densely pigmented.

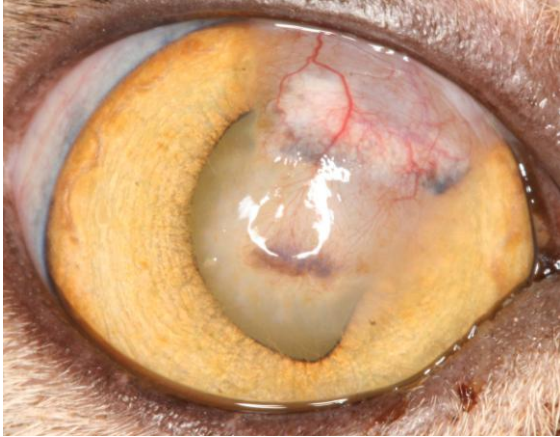

Fig 10 – The eye in Figure 1 six weeks after a corneo-conjunctival transposition surgery. The cornea has healed well and vascularisation and opacity are expected to reduce further.

5. What is the prognosis?

The prognosis is guarded due to the potential for deepening of the sequestrum and the potential for recurrence. After natural extrusion or surgery, depending on the technique used, there may be residual corneal fibrosis which will cause a varying degree of corneal opacity and therefore vision impairment.

Although recurrence has been reported to be less common in surgically treated cases, one study found a recurrence rate of 20% in both medically and surgically treated eyes. It has been observed that corneas which retain a blood supply after healing are less likely to experience recurrence and therefore it is suggested that it is prudent to permanently leave the pedicle intact in the case of conjunctival pedicle grafts (figure 11). Incomplete keratectomy leaving residual pigment is more likely

to result in recurrence, therefore precise surgery is required.

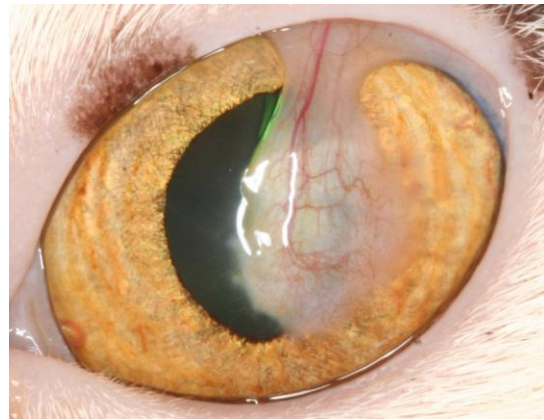


Fig 11 – The left eye of a Domestic Short-haired cat four months after a very deep sequestrum was removed and a conjunctival pedicle graft was placed. The intention is to leave the conjunctival pedicle graft in situ as the cat is functioning well with it present.

Acknowledgement:

Thanks to Tootsie Browne, the cat in figures 1, 7 and 11, and to her family.